

# Comparison of the Osteoinductive Capability of URIST™NMP to Infuse™ in an Athymic Rat Muscle Pouch Experimental Model

## Methods:

Twenty male athymic rats were divided into 4 groups of 5 animals each containing bioimplants of either demineralized bone matrix (0.2 cc DBM), Infuse™ (0.105mg rhBMP-2/0.2cc ACS, Medtronic, Minneapolis, Minnesota), URIST™NMP Fibers (0.2cc Natural Matrix Protein bioimplant, Induce Biologics, Tampa, Florida) or URIST™NMP Microparticulate (0.2cc Natural Matrix Protein bioimplant, Induce Biologics, Tampa, Florida) in both hind legs, meaning 10 implants were evaluated in each group.

Young adult (6 to 9 weeks of age) male athymic rats were quarantined for seven (7) days. The animals were anesthetized with intraperitoneal ketamine (250 mg), xylazine (11 mg), and physiological saline (10 mL) using a dosage of 3.6 mL/kg body weight. A 1 cm skin incision was made through skin parallel to the femur. Approximately midway between the hip and the knee, the membrane between the muscle groups (gluteus superficialis and the biceps femoris) was punctured with the tips of the iris scissors, and then open the scissors to stretch the puncture opening. The forceps were then opened in the opposite direction of the stretch to form a pocket between the muscle groups.

The test article was then inserted into the muscle pouch just below the femur. Both muscle pockets were sutured by placing a single suture in the muscle and the skin incision was closed with a suture. A similar procedure was then performed on the opposite leg and the same test material was placed.

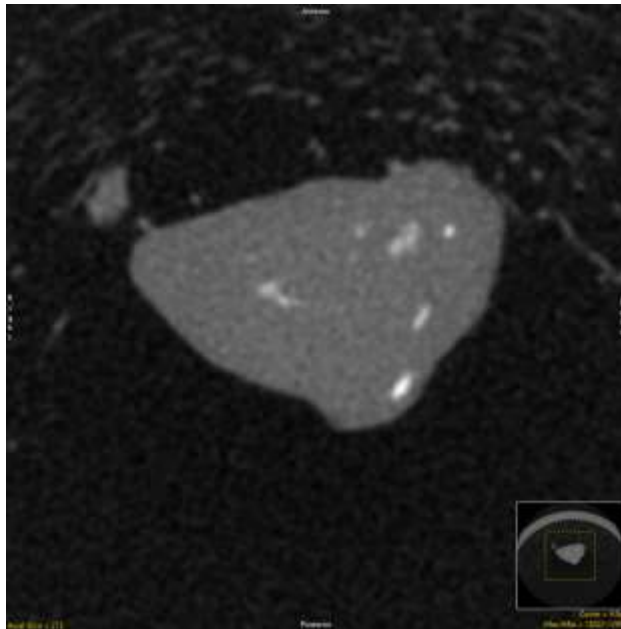
**This model is recognized by the US FDA as a method to determine the osteoinductive capability of a bioimplant.**

After 28 days the resultant tissue samples were harvested from the animals and the implant along with its surrounding tissue were fixed in 10% NBF. Once fixed the samples were analyzed by  $\mu$ CT for total explant volume, new bone volume and volumetric mineral density (a measure of the quality of bone). The data was then compared for statistical significance using an analysis of variance (ANOVA). After  $\mu$ CT analysis the implants were decalcified, embedded in wax and sectioned and stained with H&E.

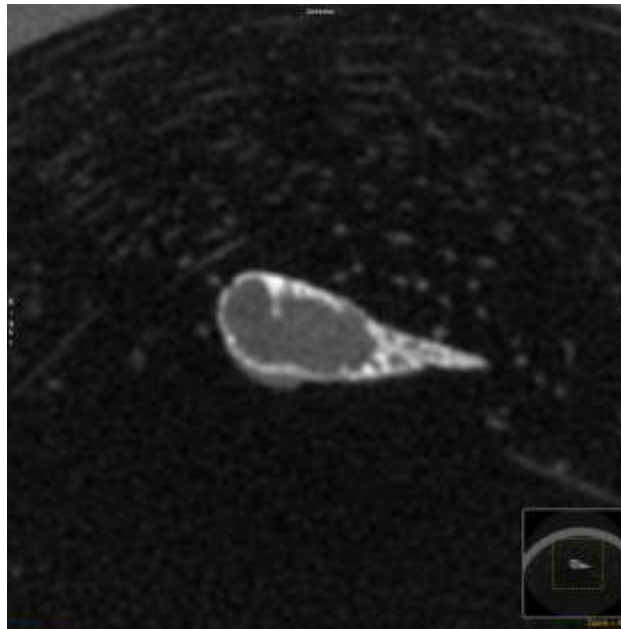
Surgeries were performed by Ibex Research, Logan Utah.  $\mu$ CT images and data collected and analyzed by separate blinded observer.

## $\mu$ CT Results

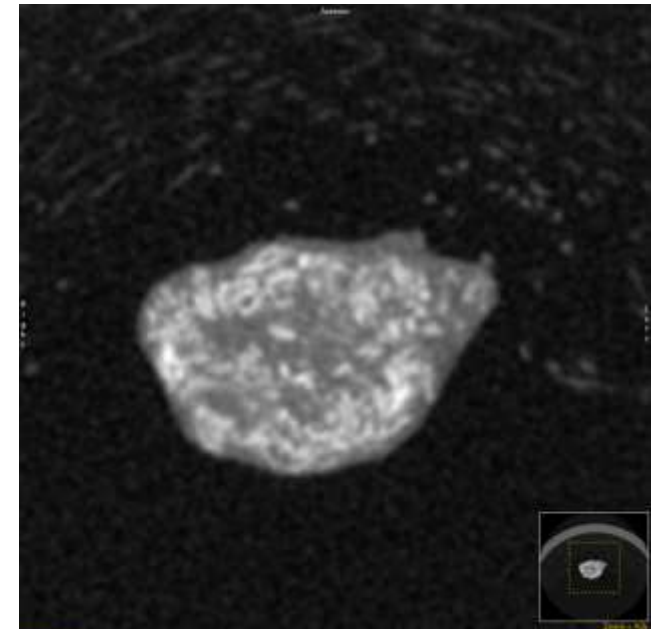
DBM



Infuse™



URIST™ NMP

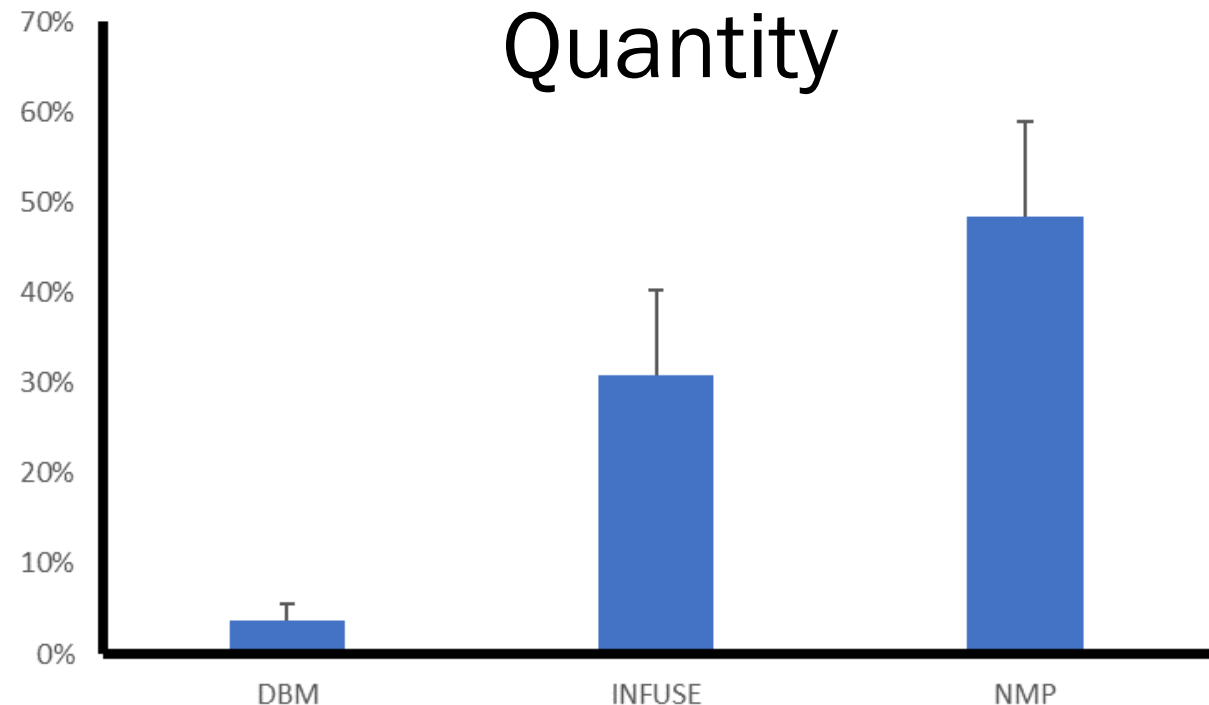


- a) **DBM:** images showed explants comprised primarily of unmineralized tissue (fibrous tissue and residual implant) with small regions of mineralized tissue (interpreted to be bone).
- b) **Infuse™:** images showed explants with a thin border of mineralized tissue surrounding a central core of unmineralized tissue.
- c) **URIST™NMP:** images showed explants consisting of a mixture of unmineralized and mineralized tissue, with the mineralized tissue (bone) occurring throughout the sample. *Note:* There were no statistically significant differences between the two NMP groups tested and as such they were grouped together for the purposes of this communication.

**Bone Volume Fraction:** The amount of mineralized tissue (new bone) formed within the bioimplant as a fraction of the volume of the entire implant.

**URIST™NMP bioimplants produced significantly more bone than Infuse™ or DBM**

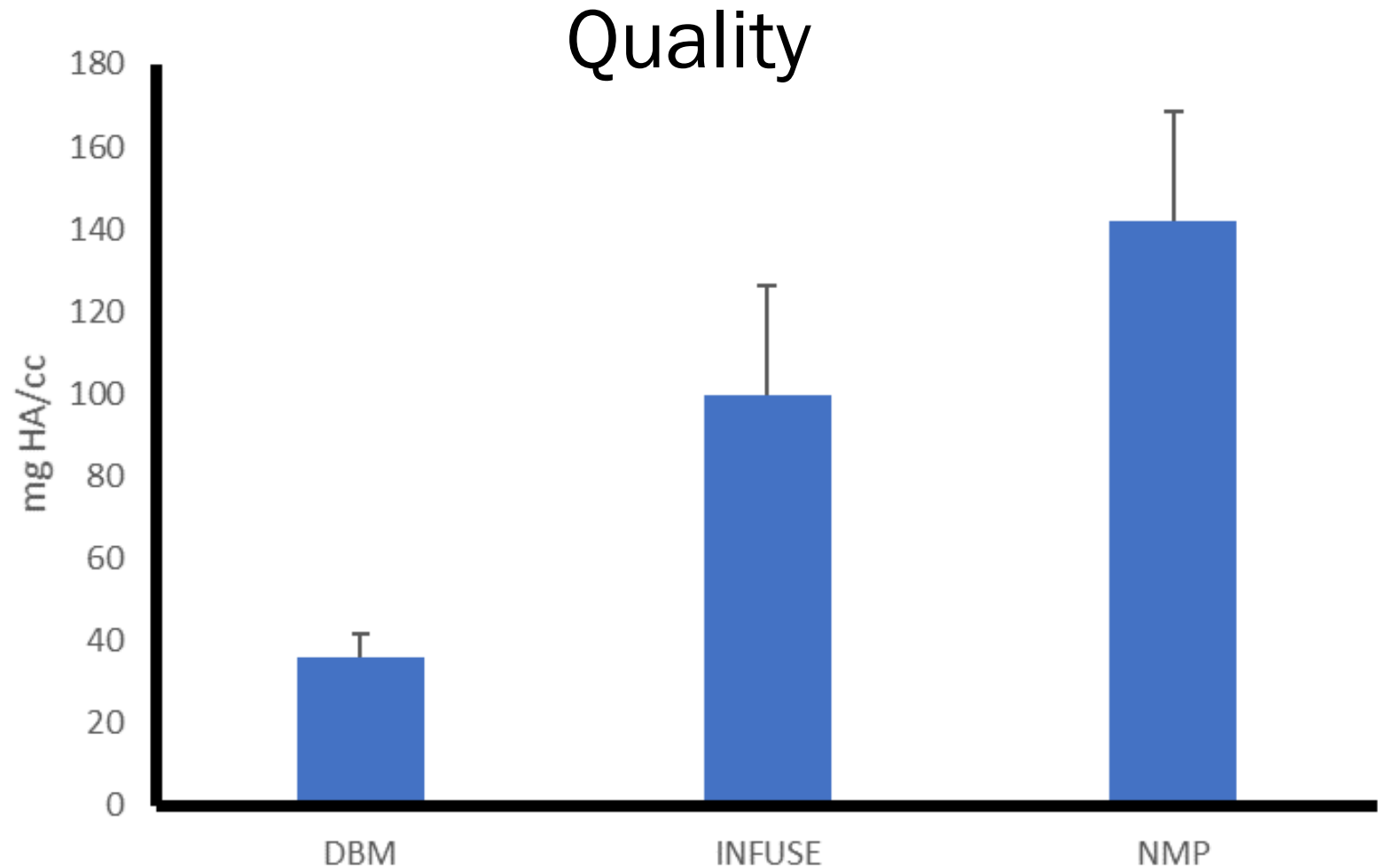
Comparison	Unadjusted P	Critical Level
NMP vs. DBM	<0.0001	0.017
INFUSE vs. DBM	<0.0001	0.025
NMP vs. INFUSE	<0.0001	0.05



**Tissue mineral density:** The volumetric mineral density of the entire explant volume expressed as mg of hydroxyapatite per cc providing information about the quality of the bone formed.

**URIST™NMP** bioimplants produced bone of significantly better quality than Infuse™ or DBM

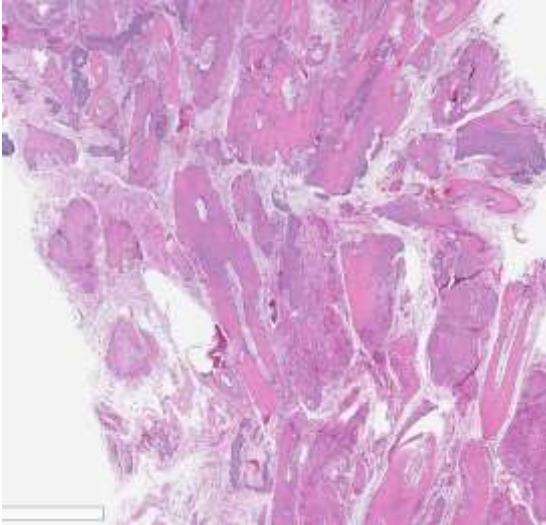
Comparison	Unadjusted P	Critical Level
NMP vs. DBM	<0.0001	0.017
INFUSE vs. DBM	<0.0001	0.025
NMP vs. INFUSE	<0.0001	0.05



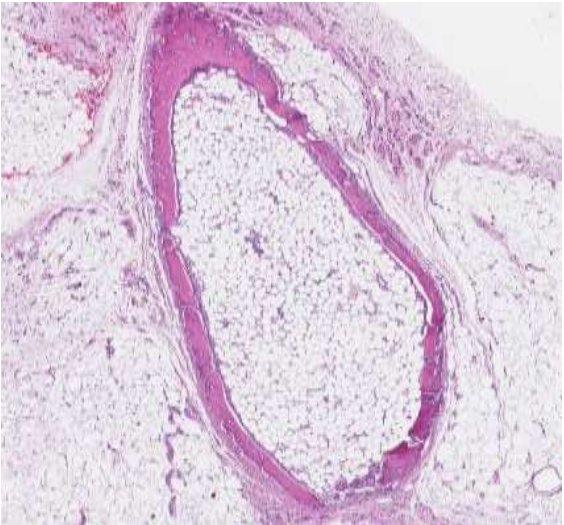

# Histology Results

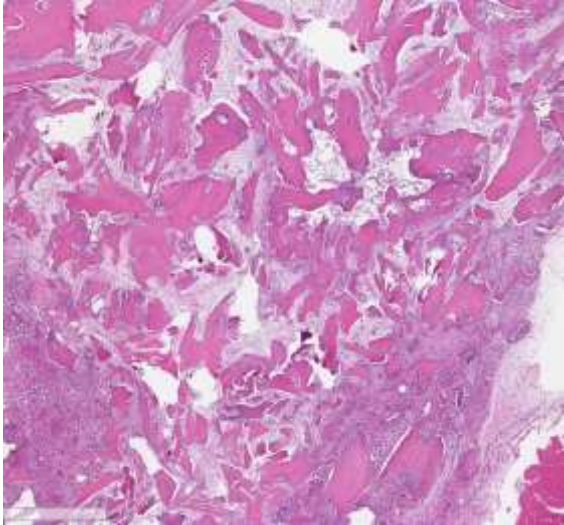
DBM



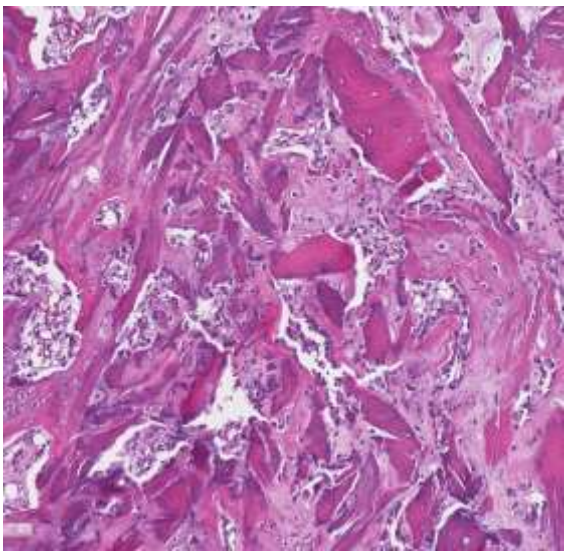
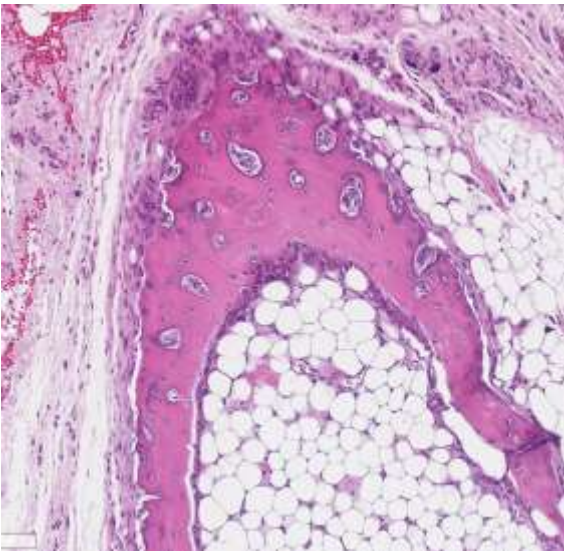
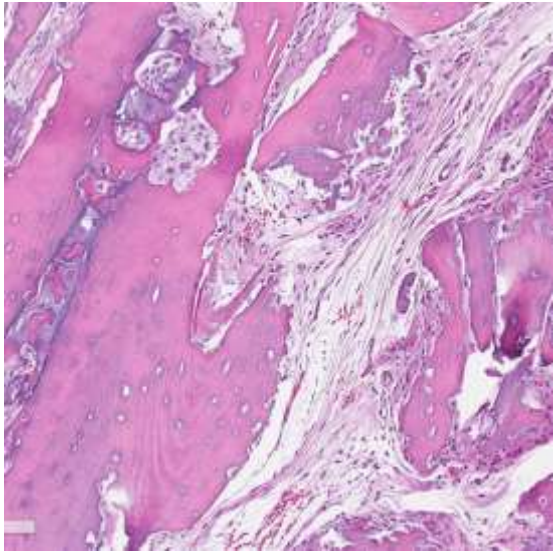
Infuse™



URIST™NMP



2x  
Magnification



10x  
Magnification

**DBM:** Samples demonstrated numerous areas of pink staining tissue surrounded by a mixed cellular infiltrate. Higher magnification demonstrated empty cell lacunae reflecting the presence of non vital bone. A few focal areas of new bone activity can be seen in the sections.

**Infuse™:** Samples demonstrated a ring of new bone surrounding a central core of vacuolated tissue. The central core is largely acellular, however, some bone forming elements are seen on the inner layer of the new bone at higher power. Evidence of inflammatory infiltrates were seen in the surrounding tissue (not shown).

**URIST™NMP:** Samples demonstrated numerous areas of small non vital tissue particles surrounded deeply stained, highly cellular activity. At higher magnification a large amount of new bone and related cellular activity was seen through out the samples. No differences were seen in the various formats of NMP treated bioimplants (results not shown).

## Conclusions:

- ❑ **URIST™NMP** demonstrated the ability to produce significantly more mineralized tissue (bone) than did the Infuse™ or the DBM bioimplants. These results were highly statistically significant. The histological samples supported the  $\mu$ CT findings.
- ❑ **URIST™NMP** demonstrated the ability to produce mineralized tissue (bone) of a significantly better quality than did the Infuse™ or the DBM bioimplants. These results were highly statistically significant. The histological samples supported the  $\mu$ CT findings.

# Part II:

## Methods:

Forty male athymic rats were divided into 8 groups of 5 animals each containing bioimplants: 1. demineralized bone matrix (0.2 cc DBM), 2. Infuse™ (0.105mg rhBMP-2/0.2cc ACS, Medtronic, Minneapolis, Minnesota), 3. URIST™NMP Fibers (0.2cc Natural Matrix Protein bioimplant, Induce Biologics, Tampa, Florida) or URIST™NMP Microparticulate (0.2cc Natural Matrix Protein bioimplant, Induce Biologics, Tampa, Florida), 4. iFactor (0.2cc, Cerapedics, Bloomfield, CO), 5. OsteoAMP (0.2cc, Bioventus, Durham, NC), 6. OsteoFactor (0.2cc, Xtant Medical, Belgrade, MT), 7. Vivagen (0.2cc, Depuy, Warsaw, IN) 7. Vivagen, and 8. Trinity Elite (0.2cc, OsteoMed, Addison TX) in both hind legs, meaning 10 implants were evaluated in each group.

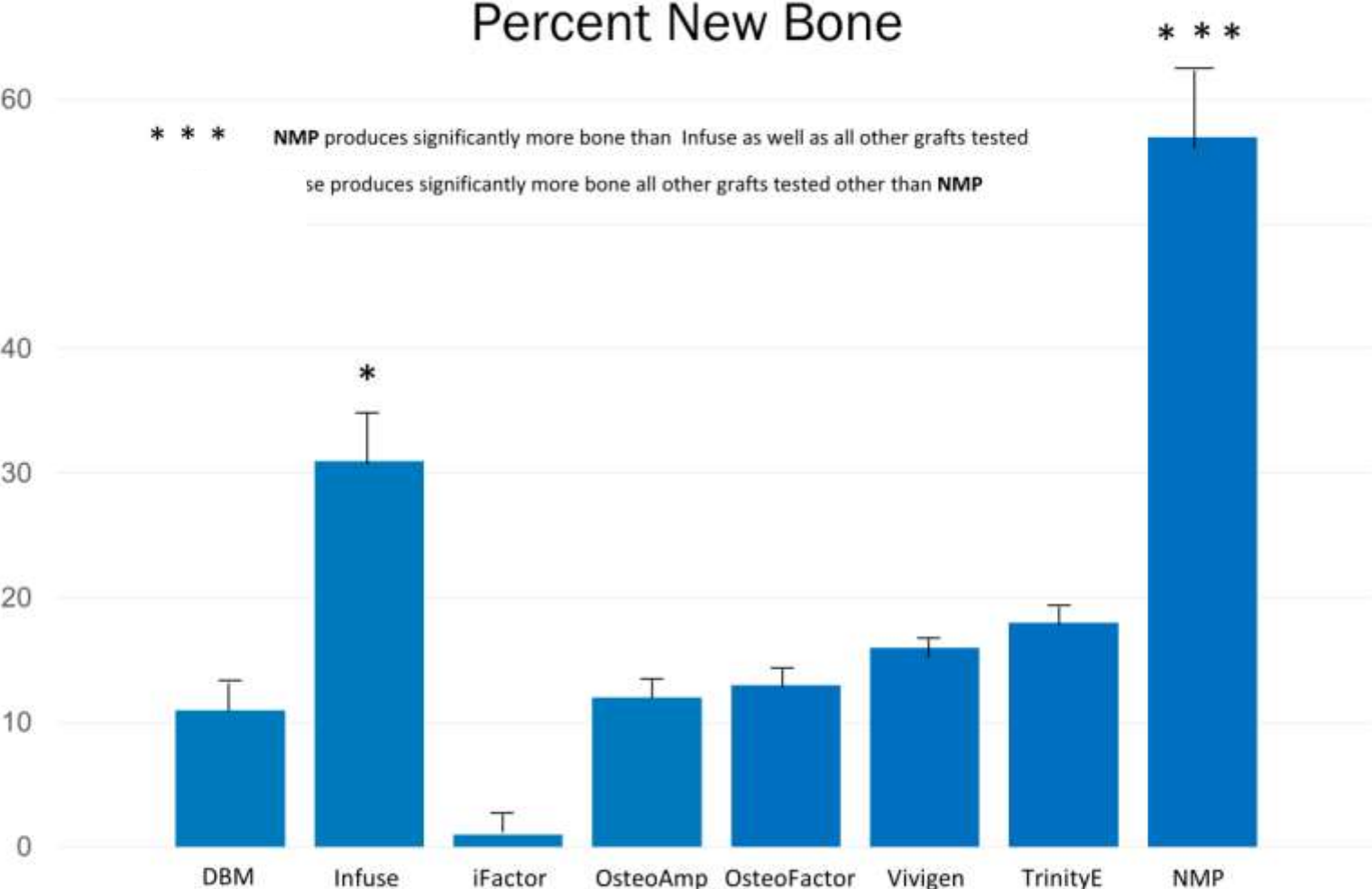
Young adult (6 to 9 weeks of age) male athymic rats were quarantined for seven (7) days. The animals were anesthetized with intraperitoneal ketamine (250 mg), xylazine (11 mg), and physiological saline (10 mL) using a dosage of 3.6 mL/kg body weight. A 1 cm skin incision was made through skin parallel to the femur. Approximately midway between the hip and the knee, the membrane between the muscle groups (gluteus superficialis and the biceps femoris) was punctured with the tips of the iris scissors, and then open the scissors to stretch the puncture opening. The forceps were then opened in the opposite direction of the stretch to form a pocket between the muscle groups.

The test article was then inserted into the muscle pouch just below the femur. Both muscle pockets were sutured by placing a single suture in the muscle and the skin incision was closed with a suture. A similar procedure was then performed on the opposite leg and the same test material was placed.

**This model is recognized by the US FDA as a method to determine the osteoinductive capability of a bioimplant.**

# Results

**URIST™NMP** bioimplants produced significantly more bone than Infuse™ or any other bioimplant tested in this study



## Conclusions:

URIST™NMP demonstrated the ability to produce significantly more mineralized tissue (bone) than did the Infuse™ or any of the bioimplants tested. These results were highly statistically significant. The histological samples supported the  $\mu$ CT findings.